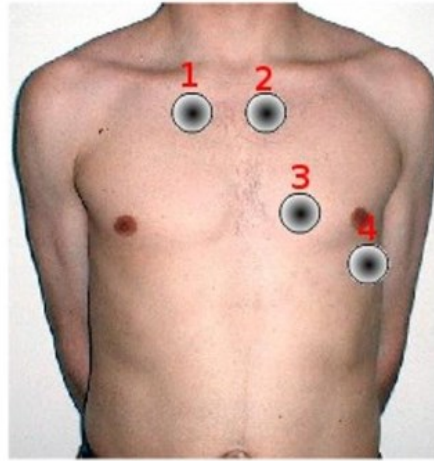
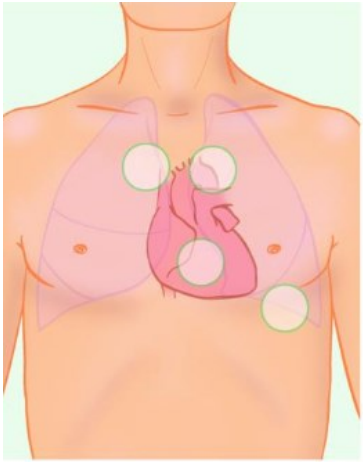
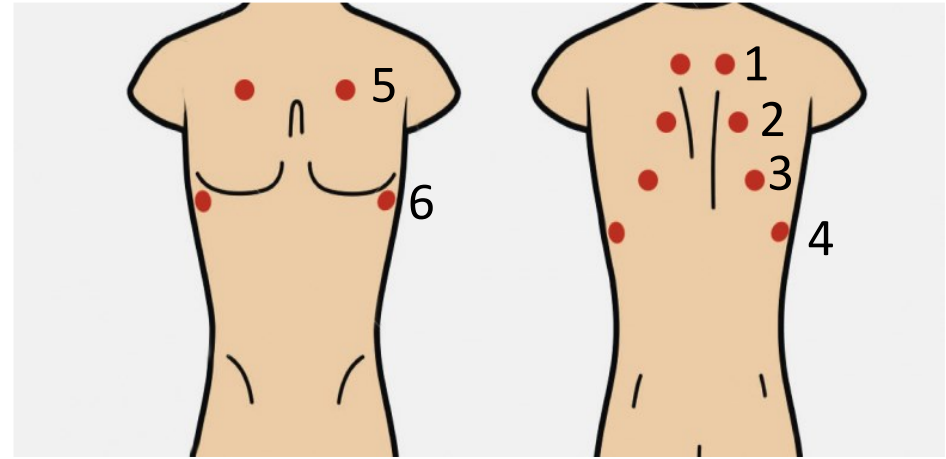


Auscultation cardiaque



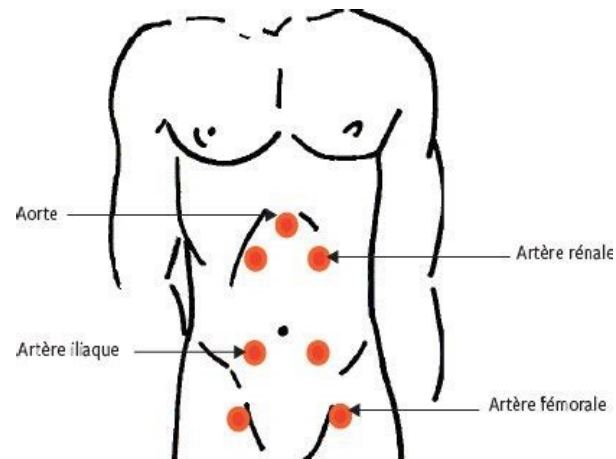
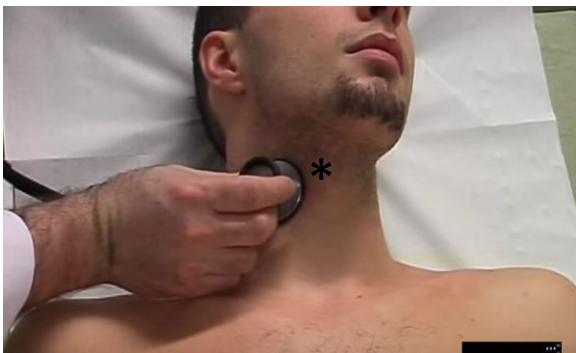
- 1 Foyer aortique
- 2 Foyer pulmonaire
- 3 Foyer tricuspide
- 4 Foyer mitral

Auscultation pulmonaire



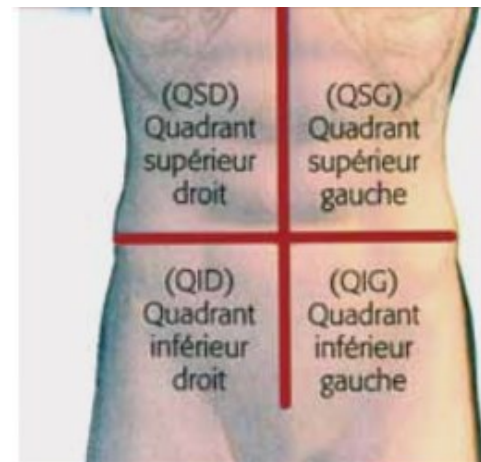
- 1 Foyer apical
- 2 Foyer médio-dorsal supérieur
- 3 Foyer médio-dorsal inférieur
- 4 Foyer basal
- 5 Foyer sous claviculaire

Auscultation des axes vasculaires



* Foyer carotidien

Auscultation abdominale



Source : Brûlé et al., 2002 (reproduction autorisée).